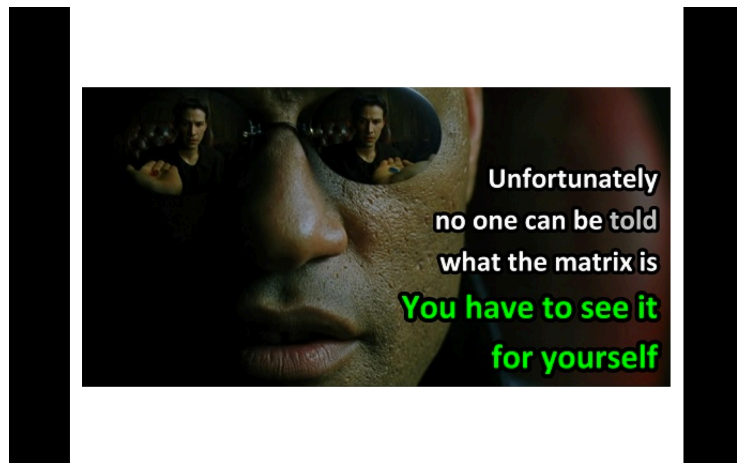


1 minute read

THE MATRIX

BY MALCOLM MCKENZIE



- Drain the subungual haematomas
- Intact nails can probably be left in place
- Obvious lacerations may do well with partial nail removal
- Proximally avulsed nails should be replaced
- Own nail is best graft
- Glue is acceptable for most lacerations and implantations
- Complex stellate lacerations may require repair
 - Absorbable 6-0, cut above knots
- Change dressing in 5-7 days, inspect wound
- Suture removal at 2-3 weeks
- Nail frequently adheres to the nail bed until pushed off by new nail

Lacerationrepair.com

<https://emergencymedicinebythesea.org/2017/03/16/the-matrix/>